

The Journal of  
**Thoracic and Cardiovascular Surgery**

**Video-assisted minimally invasive surgery for lone atrial fibrillation: A clinical  
report of 81 cases**

Yong-qiang Cui, Yan Li, Feng Gao, Chun-lei Xu, Jie Han, Wen Zeng, Ya-ping Zeng,  
Emin Gurbanov and Xu Meng

*J Thorac Cardiovasc Surg* 2010;139:326-332

DOI: 10.1016/j.jtcvs.2009.04.029

The online version of this article, along with updated information and services, is  
located on the World Wide Web at:

<http://jtcvs.ctsnetjournals.org/cgi/content/full/139/2/326>

*The Journal of Thoracic and Cardiovascular Surgery* is the official publication of the American  
Association for Thoracic Surgery and the Western Thoracic Surgical Association. Copyright ©  
2010 American Association for Thoracic Surgery

## Video-assisted minimally invasive surgery for lone atrial fibrillation: A clinical report of 81 cases

Yong-qiang Cui, MD, PhD, Yan Li, MD, Feng Gao, MD, PhD, Chun-lei Xu, MD, Jie Han, MD, Wen Zeng, MD, Ya-ping Zeng, PhD, Emin Gurbanov, PhD, and Xu Meng, MD

**Objective:** We sought to evaluate the feasibility and efficacy of a new type of video-assisted minimally invasive surgery for patients with atrial fibrillation.

**Methods:** Between December 2006 and February 2008, 81 patients with lone atrial fibrillation (49 with paroxysmal, 17 with persistent, and 15 with long-standing persistent atrial fibrillation) underwent this therapy with a bipolar radiofrequency ablation system. The main surgical procedures included bilateral pulmonary vein antrum isolation, obliteration of the left atrial appendage, division of the ligament of Marshall, and intraoperative electrophysiologic testing.

**Results:** The mean operation duration was 2.5 hours. One (1.2%) case was confirmed of left atrial appendage thrombus during the procedure. One (1.2%) patient was converted to sternotomy during the operation. Reintubation occurred in 1 (1.2%) patient, and acute heart failure occurred in 1 (1.2%) patient. One (1.2%) patient died of cerebral infarction 1 month after the operation. Follow-up was done between 3 and 19 months (mean,  $12.7 \pm 3.9$  months) after the operation. At discharge, 72.5% (58/81) of all patients were in sinus rhythm (paroxysmal atrial fibrillation, 83.7%; persistent atrial fibrillation, 64.7%; and long-standing persistent atrial fibrillation, 40.0%). At 3 months, overall 78.5% (62/79) were in sinus rhythm (paroxysmal atrial fibrillation, 85.7%; persistent atrial fibrillation, 82.4%; and long-standing persistent atrial fibrillation, 46.2%). At 6 months, overall 78.5% (62/79) were in sinus rhythm (paroxysmal atrial fibrillation, 85.7%; persistent atrial fibrillation, 70.6%; and long-standing persistent atrial fibrillation, 61.5%). At 12 months, overall 79.6% (39/49) were in sinus rhythm (paroxysmal atrial fibrillation, 80.0%; persistent atrial fibrillation, 75.0%; and long-standing persistent atrial fibrillation, 66.7%). At 18 months, 88.9% (8/9) of the paroxysmal group were in sinus rhythm.

**Conclusions:** This minimally invasive technique proves to be safe and less traumatic and presents optimistic early outcomes for patients with paroxysmal and persistent atrial fibrillation. It might find wider application if more ablation lesions could be enrolled for long-standing persistent atrial fibrillation. (*J Thorac Cardiovasc Surg* 2010;139:326-32)

Atrial fibrillation (AF) affects proximately 10 million persons in China,<sup>1</sup> undoubtedly the largest demographic group in the world, including 3 million plus persons with lone AF.<sup>2</sup> As a target group, patients with lone AF receive traditional catheter ablation, which causes endocardial trauma, fluoroscopy, therapeutic thrombus, and a high reablation rate. Video-assisted minimally invasive surgery is a newly developed technique for surgical treatment of AF, showing merits of minimal invasion, high single cure rate, and low operative risks.<sup>3</sup> Between December 2006 and February 2008, 81 drug-resistant and symptomatic patients with lone AF received this video-assisted minimally invasive surgery at

the Atrial Fibrillation Centre, Beijing Anzhen Hospital. As the largest research group in Asia, we review our early experience of clinical application of this technique and discuss the feasibility and key results of this research.

### MATERIALS AND METHODS

#### Patient Selection

Between December 2006 and February 2008, 81 patients with lone AF underwent the procedure. The institutional review board approved the research protocol, and informed consent was received from all patients. Indications for the minimally invasive therapy in this study were drug-refractory lone AF, including paroxysmal, persistent, and long-standing persistent AF, according to the Heart Rhythm Society/European Heart Rhythm Association/European Cardiac Arrhythmia Society Expert Consensus Statement,<sup>4</sup> age less than 70 years; failed catheter ablation; history of stroke or embolism; and left atrial appendage (LAA) thrombus. The exclusive criteria were left atrial dimension of greater than 70 mm, left ventricular ejection fraction of less than 30% with ultrasonic cardiographic (UCG) evaluation, previous cardiac surgery, and severe pleural adhesions. Among the 81 patients, 4 (4.9%) had failed catheter therapy. Patient characteristics are detailed in Table 1. Preoperative AF-related histories are listed in Table 2.

From the Atrial fibrillation Center, Anzhen Hospital, Beijing, China.

Disclosures: None.

Received for publication Feb 26, 2008; revisions received Feb 27, 2009; accepted for publication April 28, 2009; available ahead of print July 27, 2009.

Address for reprints: Xu Meng, MD, Department of Cardiac Surgery, Beijing Anzhen Hospital, Beijing (100029), P.R. China (E-mail: mxu@263.net).

0022-5223/\$36.00

Copyright © 2010 by The American Association for Thoracic Surgery

doi:10.1016/j.jtcvs.2009.04.029

### Abbreviations and Acronyms

AF	= atrial fibrillation
ECG	= electrocardiography
GP	= ganglionic plexi
ICS	= intercostal space
IVC	= inferior vena cava
LAA	= left atrial appendage
PV	= pulmonary vein
RF	= radiofrequency
RSPV	= right superior pulmonary vein
SR	= sinus rhythm
SVC	= superior vena cava
TEE	= transesophageal echocardiography
UCG	= ultrasonic cardiography

### Preoperative Management

Patients underwent a detailed preoperative evaluation. Baseline 12-lead electrocardiographic (ECG) analysis, chest radiographic scanning, transthoracic UCG and transesophageal echocardiographic (TEE) analysis, computed tomographic scanning, stress testing, or coronary angiographic analysis were performed on admission. Meanwhile, daily respiratory exercises were also recommended. All patients were required to fill out a questionnaire about their AF history, antiarrhythmia drug use, New York Heart Association heart function, history of stroke, and so on.

### Surgical Technique

We followed the technique that has been previously reported.<sup>3</sup> This technique was demonstrated to us by Dr Randall Wolf and consists of epicardial radiofrequency (RF) isolation of the bilateral pulmonary vein (PV) antrum, ligation of the LAA, and electrophysiologic testing. Overall, the ablation is performed with an Isolator Transpolar ENDO ablation clamp (AtriCure, West Chester, Ohio) and the Wolf Lumitip-Dissector (AtriCure). Two pacing and sensing devices (Detect and Carelink 2090 programmer; Medtronic, Minneapolis, Minn) are designed as a unit to perform intraoperative testing. An EZ-45G Endostapler (Johnson and Johnson Medical, Inc, Arlington, Tex) was used to remove the LAA.

**Right-sided ablation.** General anesthesia is administered with a double-lumen endotracheal tube for single-lung ventilation. In some patients electric cardioversion is attempted during anesthesia, either before or after the left-sided procedure. The patient is placed in the left lateral decubitus position and turned 45° to 60°. The first port (10 mm) is introduced in the sixth intercostal space (ICS) approximately 1 cm anterior to the midaxillary line. The right lung is deflated. A 10-mm 30° thoracoscope is inserted through the port to visualize the right hemithorax. After counting ribs internally to verify the location of the third ICS, a 5-cm right external thoracic incision at the third ICS between the anterior and midaxillary lines is made, serving as the working port (Figure 1).

A Medium Soft-Tissue Retractor (Cardioventions; Ethicon GmbH, Nordstedt, Germany) is inserted through working port, locating the right phrenic nerve on the pericardium. Then an opening in the pericardium 2 to 3 cm anterior and parallel to the phrenic nerve is made, exposing the heart 3 cm superior to the superior vena caval (SVC)-atrial junction. The pericardium should be opened inferiorly as far as possible (to the diaphragm). Pericardial stay sutures (2 to 3) are placed in the posterior cut pericardial edge and are anchored laterally through stab sites. We then identify anatomic structures, such as the SVC, right superior pulmonary vein (RSPV), right inferior PV, inferior vena cava (IVC), and right pulmonary artery.

**TABLE 1. Preoperative data**

Characteristics	Results
Male/female sex	51/30
Age at operation (y)	57.6 ± 10.0
Paroxysmal AF	49
Persistent AF	17
Long-standing persistent AF	15
NYHA class I, n (%)	70 (86.4)
NYHA class II, n (%)	11 (13.6)
LA diameter (mm)	49.7 ± 11.4
Duration of AF (y)	5.9 ± 4.9

AF, atrial fibrillation; NYHA, New York Heart Association; LA, left atrium.

Baseline sensing and pacing of the RSPV and right inferior PV and bifurcation of the right PV are performed, and then ganglionic plexi (GP) activity is detected. Both PV antrum and GP detection were done before application of RF through the clamp and after RF application.

Afterward, a pediatric Yankauer suction is applied through a working port to begin initial dissection between the SVC and RSPV. A space from the superior aspect of the RSPV posteriorly and a space just inferior to the IPV and lateral to the IVC into the oblique sinus are bluntly developed. The second Port (10 mm) is made either medially or laterally to the scope port for Wolf Lumitip Dissector use. Then the dissector is introduced through the port site and into the pericardial space. The dissector tip is fed into the oblique sinus just above the IVC. The distal end of the dissector tip is advanced posteriorly and then swept medially into position behind the right PVs. The device is advanced superiorly in the oblique sinus to reflections at the superior edge of the SPV just under the SVC.

The dissector tip is advanced past the SPV and articulated anteriorly, as necessary, until the tip is exposed beneath the reflection. The dissector is teased through the reflection under direct visualization. Dissection is complete when the dissector tip is clearly visible and the tip is free from tissue.

A transfer red rubber catheter is attached to the dissector tip. Then, after disarticulating the dissector, it is slowly retracted with the red rubber catheter attached, and the dissector is removed from the port site. The lower jaw of the Isolator Transpolar ENDO ablation clamp with the red rubber catheter is clipped. Afterward, the red rubber catheter should lead the lower jaw of the isolator clamp into the desired dissection plane posterior to the RPVs. The isolator clamp is advanced until the posterior tip is visible above the RSPV. The red rubber catheter is removed from the distal end of the lower jaw. One should ensure that the isolator jaws are clamped over the atrial cuff as much as possible, especially inferiorly. Then repetitive ablations are applied at most 5 times, with a 2-mm distance among each lesion moving toward the atrial cuff. The isolator clamp is removed. The pericardial stay sutures are removed, and the pericardium does not need to be closed on the right side, but epicardial pacing leads are routinely placed. A 20F chest tube is placed through one of the inferior port sites. The right lung is re-inflated, and incisions are closed.

**Left-sided ablation.** The patient is repositioned in the right lateral decubitus position and turned 45° to 60°. The incisions, electrophysiologic, dissection, and ablation procedures are performed in a fashion similar to those for the right side besides opening the pericardium 2 to 3 cm posterior and parallel to the phrenic nerve, and ligament of Marshall is cut off under direct vision.

The LAA is excluded after the left PVs have been isolated. The EZ-45G Endostapler should be introduced through one of the inferior port sites. The LAA is gently manipulated into the stapler jaws, and the position of the circumflex coronary artery outside the stapler is verified. The stapler is closed and fired. It is highly recommended that the staple be kept in position for 5 seconds, and then the stapler and LAA are removed. Hemostasis is verified, and the pericardium is closed. A 20F chest tube is inserted through one of the port holes. The left lung is inflated, and the incisions are closed in a similar fashion (Figure 2).

TABLE 2. Preoperative AF-related histories

Characteristics	Results, n (%)
Hypertension	31 (38.2)
Alcoholic history	15 (18.5)
Smoking history	19 (23.5)
Stroke/arterial embolism	12 (14.8)
Diabetes	4 (4.9)
Hyperthyroid	2 (2.5%)
Catheter ablation	4 (4.9)
Permanent pacemaker implantation	2 (2.5)
Digoxin	17 (21.0)
Betaloc	48 (59.3)
Amiodarone	45 (55.6)
Aspirin	69 (85.2)
Warfarin	23 (28.4)

AF, Atrial fibrillation.

### Electrophysiologic Testing

Intraoperative electrophysiologic testing was performed, which includes bilateral PV antrum, baseline and postisolation sensing and pacing, and GP detection. A baseline positive sensing result (rapid and disorderly atrial potentials) in the PV antrum area could be detected before PV isolation, and a negative sensing result (no atrial potentials) could be detected in the same area after ablation, which is called entrance block. A positive baseline pacing result is defined as the atrial and ventricular capture and is obtained. Capture is the contraction of the atrium and ventricle in response to the electrical stimulus being sent from the temporary pacemaker (Oscor Pace 203H DDD External Dual-Chamber Pacemaker; Oscor Inc, Palm Harbor, Fla). A negative postablation pacing result means that no capture is obtained in the same area after ablation. A combined positive baseline pacing and negative postablation pacing result is called exit block. Achieving both entrance and exit block is regarded as a transmural lesion blocking the conduction in the PV antrum area. Meanwhile, GP activity detection is included in the electrophysiologic testing procedure, as in the experience of Mehall and colleagues,<sup>5</sup> which is basically mapped by using a high-frequency stimulus (10 V, 800 times per second) for 5 seconds or more. A positive response was defined as sinus bradycardia (<40 beats/min) or asystole, atrioventricular block, or hypotension occurring ventricular asystole of the onset of high-frequency stimulus.<sup>6</sup>

### Postoperative Medical Management

Amiodarone was administered to 79 (97.5%) patients at approximately 100 to 200 mg/d for 3 months after the operation and was then tapered off in the presence of a stable sinus rhythm (SR). Meanwhile, metoprolol tartrate (Betaloc; AstraZeneca, Inc, London, United Kingdom) was also used in combination with amiodarone postoperatively based on average heart rate.

Postoperative anticoagulation follows the instructions found in the American College of Cardiology/American Heart Association/European Society of Cardiology guidelines.<sup>7</sup> The option of the use of warfarin or aspirin is based on the patient's CHADS score. Anticoagulant drug is discontinued if SR is present, and then 24- or 48-hour Holter monitoring reveals SR at 4 months. An AF/atrial flutter episode is present if it is documented by means of ECG or Holter monitoring and lasts at least 30 seconds.<sup>4</sup>

During the follow-up period, if ECG analysis shows recurrence of AF or atrial flutter sustained for more than 8 hours, a direct-current cardioversion is recommended.

### Follow-up

Follow-up was obtained from office visits at an outpatient building, mailed medical records received from local hospitals, and questionnaires. Twelve-lead ECG analysis, 24- to 48-hour Holter monitoring (for patients in SR with ECG), and transthoracic UCG were evaluated at discharge and 1, 3, 6 and 12 months postoperatively. Free ECG examinations and free 24- to 48-hour Holter monitoring (Del Mar Reynolds Medical, Inc, Irvine, Calif) were offered at the Atrial Fibrillation Centre, Beijing Anzhen Hospital. A database for this minimally invasive procedure was set up for this study.

### Statistical Analysis

Standard descriptive statistics were applied. Values are expressed as means  $\pm$  standard deviations. Outcomes of rhythms were descriptively analyzed at interval contacts. Meanwhile, Kaplan-Meier analysis was used for time-related freedom from AF in the paroxysmal AF group. All *P* values are 2-tailed.

## RESULTS

### Operative Results, Morbidity, and Mortality

Two (2.5%) patients had preoperative permanent pacemaker implantation because of sick SR. Mean duration of the procedure was 2.5 hours. Mean bleeding was 81 mL. The first 10 patients did not have LAA obliteration because

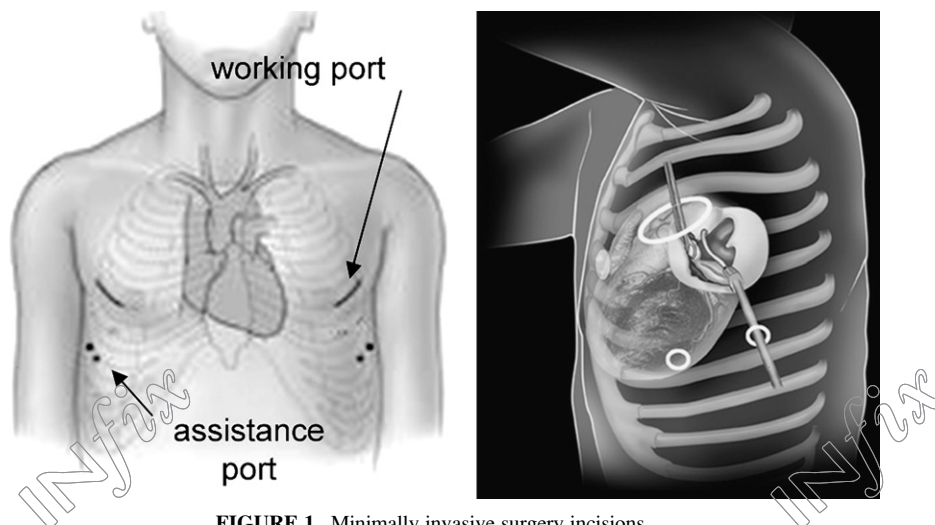
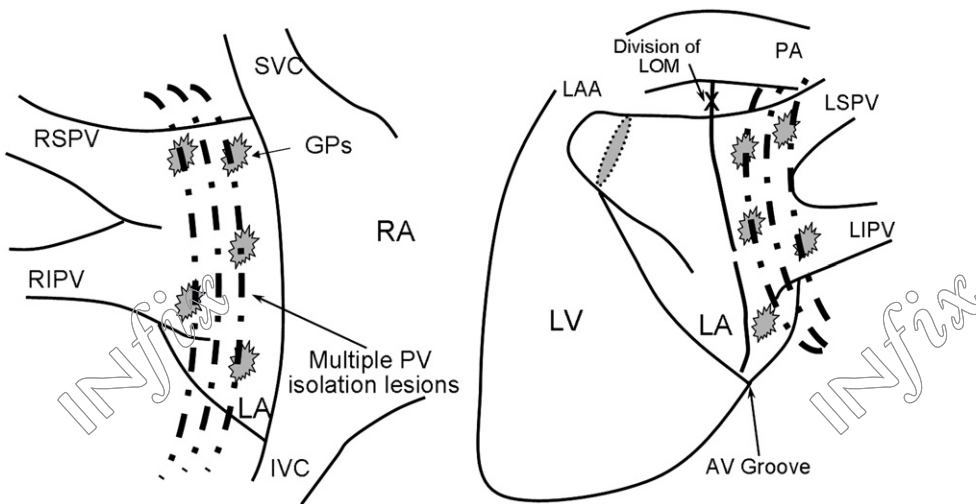


FIGURE 1. Minimally invasive surgery incisions.



**FIGURE 2.** Lesion set of minimally invasive surgery. SVC, Superior vena cava; RSPV, right superior pulmonary vein; GPs, ganglionic plexi; RA, right atrium; RIPV, right inferior pulmonary vein; PV, pulmonary vein; LA, left atrium; IVC, inferior vena cava; LAA, left atrial appendage; LOM, ligament of Marshall; PA, pulmonary artery; LSPV, left superior pulmonary vein; LIPV, left inferior pulmonary vein; LV, left ventricle; AV, atrioventricular.

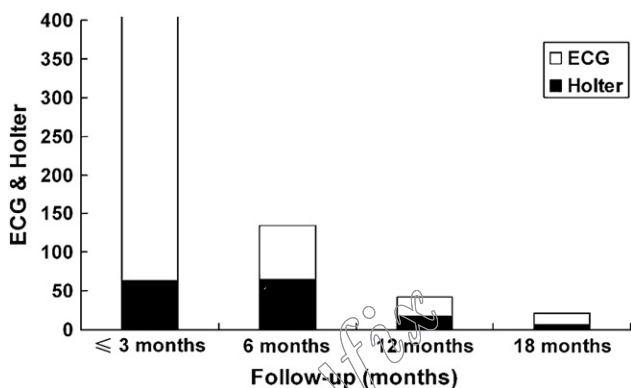
of a lack of right endoscopic cutters. None of them had cerebrovascular events during follow-up. Three (3.7%) patients had LAAs removed before ablation because preoperative TEE and computed tomographic scanning indicated abnormal density in the LAA. One of the 3 patients was confirmed to have thrombus after LAA excision, whereas the other 2 were proved to have thickened trabeculae in the LAA. One (1.2%) case was converted to sternotomy after the occurrence of bleeding during right inferior PV dissection. One (1.2%) patient had acute cardiac dysfunction caused by subendocardial infarction and recovered within 12 days. One (1.2%) patient had reintubation caused by hypoxemia in the intensive care unit. Two (2.5%) patients had wound exudation. One (1.2%) patient died of cerebral infarction 1 month after the operation. Mean postoperative hospitalization was  $4.5 \pm 2.7$  days. Follow-up ranged between 3 and 19 months (mean,  $12.7 \pm 3.9$  months). Cardioversion was performed in 18 (22.2%) patients before

discharge and during follow-up. Overall morbidity was 7.4%, and postoperative stroke rate was 1.2%.

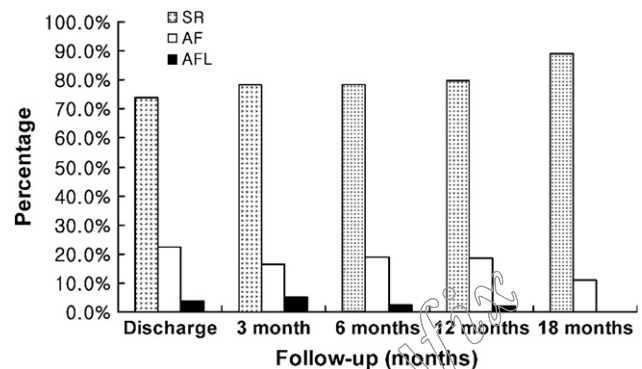
**Heart Rhythm**

One patient was lost to follow-up after discharge. Eighty patients had a total of 452 ECG examinations during follow-up, a mean of 5.7 examinations per patient. Twenty-four-hour Holter monitoring was done in 77 (96.3%) patients, and 48-hour Holter monitoring was done in 3 (3.7%) patients (Figure 3). Ten (12.3%) patients stopped taking amiodarone at 1 month, with 69 (85.2%) patients stopping the drug at 3 months.

At discharge, 72.5% (58/81) of all patients were in SR (paroxysmal AF, 83.7%; persistent AF, 64.7%; and long-standing persistent AF, 40.0%). At 3 months, overall 78.5% (62/79) were in SR (paroxysmal AF, 85.7%; persistent AF, 82.4%; and long-standing persistent AF, 46.2%). At 6 months, overall 78.5% (62/79) were in SR (paroxysmal



**FIGURE 3.** Frequencies of electrocardiographic analysis (ECG) and Holter monitoring during follow-up.



**FIGURE 4.** Overall rhythm constitution at interval contact. SR, Sinus rhythm; AF, atrial fibrillation; AFL, atrial flutter.

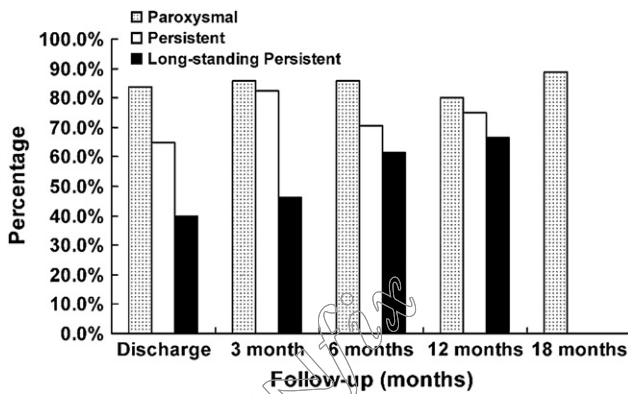


FIGURE 5. Percentage of patients in sinus rhythm in 3 groups at interval contact.

AF, 85.7%; persistent AF, 70.6%; and long-standing persistent AF, 61.5%). At 12 months, overall 79.6% (39/49) were in SR (paroxysmal AF, 80.0%; persistent AF, 75.0%; and long-standing persistent AF, 66.7%). At 18 months, 88.9% (8/9) of the paroxysmal AF group were in SR; no patients in the persistent and long-standing persistent AF groups reached 18 months' duration after the operation by the end of the research period. Rhythm constitution of 3 groups is shown in Figure 4. Restoration of SR of 3 groups at different time intervals is shown in Figure 5.

Based on Kaplan–Meier analysis, freedom from AF in the paroxysmal AF group was 97% at 6 months and 86% at 12 months (Figure 6).

### Atrial Contractility

During follow-up, atrial contraction was detected by means of transthoracic UCG among 58 (96.7%) of the 60 patients in SR. Considering a peak A-wave velocity of 10 cm/s as the cutoff point for effective atrial contractility,<sup>8</sup> among these 58 patients, 98.3% (57/58) regained atrial transport function, and only 1 patient in the long-standing persistent AF group did not show effective left atrial function despite restoration of SR.

### DISCUSSION

Surgical treatment of AF is known as presenting the longest history and best outcomes.<sup>9</sup> In recent years, with the emergence of alternative ablation energy sources, the traditional cut-and-sew technique is being replaced with ablation technology, which makes atrial lesions using these new energies and also shows promising outcomes.<sup>10,11</sup> However, because of the limitation of operative approaches, currently, the main indication of surgical ablation is still a patient with AF with a concomitant disease that requires a cardiac operation.

Aiming at patients with lone AF, the first report of a minimally invasive, epicardial ablation therapy was published in 2003.<sup>12</sup> This new off-pump, bilateral thoracoscopic PV isolation technique extends the implications of surgical therapy

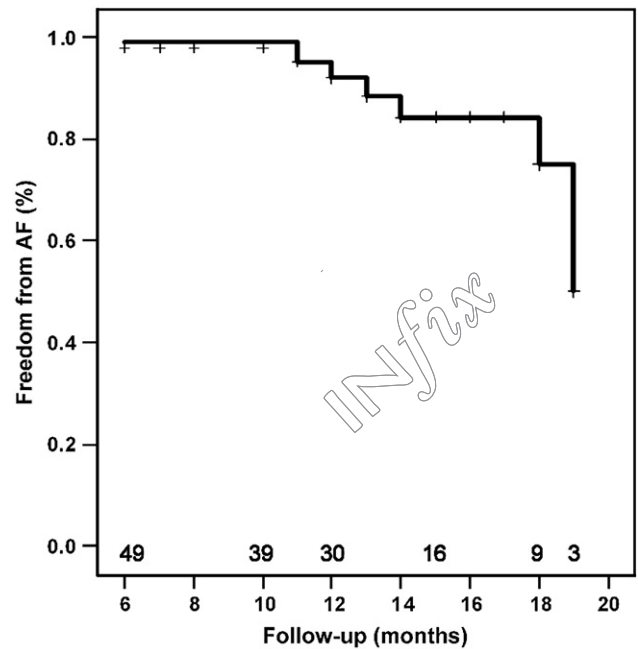


FIGURE 6. Kaplan–Meier curve demonstrating freedom from atrial fibrillation (AF) in patients with paroxysmal AF.

of AF. According to this study, the minimally invasive technique offers good early outcomes, particularly for AF with a short persistent history.

First, the results show an optimistic therapeutic effect for paroxysmal AF similar to that seen in the latest studies,<sup>5,13,14</sup> which is closely related to the multiple complete and transmural PV antrum isolation lesions that the minimally invasive technique accomplishes. Electrophysiologic studies demonstrate that the PVs and posterior left atrium are critical anatomic sites in human patients with lone AF.<sup>15,16</sup> During the minimally invasive operation, the bipolar RF clamp compresses PV antrum tissue, and energy is delivered between the jaws together with the transmural feedback algorithm, and the transmural of the isolation lesion is theoretically ensured. Furthermore, 3 to 4 lesions are made from distal to proximal atrial tissue on each side, and as a result, ectopic triggers are theoretically isolated.

In addition to the transmural algorithm and multiple isolation lesions, the epicardial electrophysiologic testing also further helps to evaluate the quality of the atrial lesion. Preablation sensing (baseline sensing) detected rapid and disorderly atrial potentials in all patients who were in AF during the operation. And postablation sensing shows 3 outcomes of the potentials in the same area: disappearance (“quiet”), regular and slow potentials as normal atrial potentials in SR, and disorderly potentials but not as intensive and rapid as before ablation. In this study re-isolation ablation will be performed if either of the latter 2 sensing potentials is detected until a “quiet” sensing field is obtained. What

**TABLE 3. Operative and postoperative data**

Patient outcomes	Results
Procedure time (h)	2.5 ± 0.8
LAA thrombus, n (%)	3 (3.7)
Sternotomy, n (%)	1 (1.2)
Acute respiratory failure, n (%)	1 (1.2)
Acute cardiac dysfunction, n (%)	1 (1.2)
Postoperative stay (d)	4.5 ± 2.7
Cardioversion, n (%)	14 (17.3)
Stroke, n (%)	1 (1.2)

LAA, Left atrial appendage.

needs to be specially mentioned is that there are possibly (27.2% [22/81]) persistent regular and small potentials sensed even if ablations were done on a certain side. Often, these diminutive potentials recorded after ablation can represent “far-field” left atrial potentials.<sup>17</sup> The effect of this “positive” postablation sensing and GP detection results on short-term and midterm therapeutic outcomes is under observation in a concurrent study. As for “exit block,” based on the baseline preablation pacing threshold in PV antrum, a 5-mV stimulus intensity is added in a stepwise manner to at most 20 mV for the postablation pacing. In this study pacing results show that all patients who were in SR after bilateral ablations did not show “atrial and ventricular capture” and accordingly achieved “exit block.”

Second, this study proves the feasibility of surgical ligation of the LAA through the minimally invasive technique. Thrombotic material associated with AF arises most frequently in trabeculated portions, such as the LAA.<sup>7,18</sup> According to the study of Odell and associates,<sup>19</sup> the thrombus was localized to the LAA in 91% of patients with nonrheumatic AF, including patients with lone AF. When combined with amputation or obliteration of the LAA, postoperative thromboembolic events are substantially reduced.<sup>7</sup> This minimally invasive technique offers a safe and easy approach to remove the LAA, even though for the first 10 patients the LAA was not obliterated because a right endoscopic cutter was not available, but during more than 12 months’ follow-up, none of these patients had cerebrovascular events.

In this research 3 patients had left thoracotomies first and LAAs excised before ablation because results of preoperative TEE and imaging indicated abnormal density in the LAA. Even though only 1 of the 3 cases of thrombus was confirmed afterward, our experience still demonstrates that, unlike other studies,<sup>14</sup> based on proper selection and valid technique, patients with lone AF with LAA thrombus can be treated with this minimally invasive therapy with an adjusted operative strategy. But patients still require anticoagulation therapy during the postoperative 4 months, even if restoration of SR presents. The therapy can be discontinued if Holter monitoring reveals stable SR at 4 months. During follow-up, 1 patient in the long-standing persistent AF group

died of stroke at 1 month. This patient had AF recurrence 2 weeks after the operation but stopped warfarin by himself because gingival bleeding occurred 4 days before the stroke. Twelve patients had a history of stroke before the operation, and only 1 (0.83%) of them was confirmed to have LAA thrombus, as mentioned above. All 12 patients were administered warfarin after the procedure, and 6 of 11 (1 was lost follow-up) were in stable SR at the latest hospital visit. Then warfarin was replaced with aspirin.

The long-standing persistent AF group shows 44.4% and 71.4% SR restoration rates at 3 and 6 months postoperatively, respectively. Similar research<sup>14</sup> also reports 67% and 72% success rates, respectively. Based on these results and other studies,<sup>20</sup> bilateral PV isolation might not be a good option for this type of AF. As for long-standing persistent AF, modification of the atrial substrate plays a more important role in the maintenance of re-entry wavelets than ectopic initiation triggers in the PV area. Therefore more atrial lesions are needed to break the re-entries than just isolating the PV antrum region for curing long-standing persistent AF. The current catheter technique has adopted a left atrial linear ablation strategy, such as with the left atrial roof and mitral annular lesions, for AF with a persistent history of more than 12 months.<sup>21</sup> Through this study, we believe that the main target of the minimally invasive technique is still paroxysmal and persistent AF. As for long-standing persistent AF, this technique should further include more atrial linear lesions with development of new technology and surgical approaches, such as the extracardiac maze procedure performed on the beating heart.<sup>22</sup> Perhaps a hybrid technique is more available at present, which means supplementing endocardial left atrial ablation with a catheter, combined with this minimally invasive operation, to reverse substrate modification of long-standing persistent AF and achieve possibly better outcomes.

This minimally invasive approach demonstrates a high degree of safety and fewer traumas. Basically, the main influences are related to general anesthesia and surgical incisions, but it still concerns patient selection and a learning curve. In this study 1 (1.2%) patient was converted to sternotomy after the occurrence of bleeding during right inferior PV dissection. Considering he was the fourth patient since our center started this operation, based on our experience, a learning curve of approximately 12 surgical procedures is a realistic expectation with the technique. One (1.2%) patient had postoperative acute respiratory failure and reintubation, which was due to a long smoking history and decrease of lung function. One (1.2%) patient had acute cardiac dysfunction caused by subendocardial infarction in spite of a negative preoperative coronary angiographic scan, and after discharge, this patient has been in stable SR according to 2 bouts of 24-hour Holter monitoring at 3 and 10 months, respectively. Despite the morbidities in this study, the minimally invasive approach still provided

high security for patients. Technically, unlike catheter ablation, this technique only applies epicardial ablation on a beating heart, without any contact with the endocardium, which avoids the risks of thrombus formation caused by foreign bodies, such as ablation devices and endocardial trauma.<sup>23,24</sup>

Furthermore, during the minimally invasive operation, under endoscopic and direct vision, the whole ablation procedure is done within the pericardial space, plus the energy flow between the 2 jaws of the bipolar clamp, and no collateral damage is observed. More importantly, the ablation is performed in the PV antrum area, and rarely complications of PV stenosis would occur.

This minimally invasive operation is a combination of both endoscopic and thoracic techniques. Thoracoscopy is used to verify the exact location of the working incision at the third ICS, which provides excellent access to bilateral PVs and GP and to assist visualization during the procedure. Most of the procedure is done by the surgeon through the small 4- to 5-cm working incision under direct vision. Therefore avoiding the full thoracoscopic technique significantly reduces the complexity and shortens the learning curve and, as a result, promotes the adaptability of this minimally invasive operation. On the other hand, this technique requires bilateral thoracic incisions and bilateral positioning during the procedure. Meanwhile, with the limitation of surgical access and bipolar RF clamping, bilateral PV isolation for paroxysmal AF is still the main target of the minimally invasive technique.

## CONCLUSIONS

Video-assisted minimally invasive surgery with the bipolar RF system with multiple PV antrum isolation lesions made and guided by means of intraoperative electrophysiologic testing has been proved to be an effective, easy, and safe technique for AF, particularly for patients with paroxysmal AF. Future studies should emphasize how to enroll patients with long-standing persistent AF, probably by adapting a new approach to apply a more extensive procedure for optimistic therapeutic effects.

We thank Shu-ping Ding for her assistance in data collection.

## References

- Huang C, Ma C, Yang Y, Huang S, Zhang S, Jiang H, et al. Current knowledge and management recommendations of atrial fibrillation (II). *Chin J Cardiac Arrhythmias*. 2006;10:167-97.
- Zhou Z, Hu D, Chen J, Zhang R, Li K, Zhao X. An epidemiological survey of atrial fibrillation in China. *Chin J Intern Med*. 2004;43:491-4.
- Randall K, Wolf RK, Schneeberger EW, Osterday R, Miller D, Merrill W, et al. Video-assisted bilateral pulmonary vein isolation and left atrial appendage exclusion for atrial fibrillation. *J Thorac Cardiovasc Surg*. 2005;130:797-802.
- Calkins H, Brugada J, Packer DL, Cappato R, Chen S-A, Crijns HJG, et al. HRS/EHRA/ECAS expert consensus statement on catheter and surgical ablation of atrial fibrillation: recommendations for personnel, policy, procedures and follow-up: a report of the Heart Rhythm Society (HRS) Task Force on Catheter and Surgical Ablation of Atrial Fibrillation. *Heart Rhythm*. 2007;4:816-61.
- Mehall JR, Kohut RM Jr, Schneeberger EW, Taketani T, Merrill WH, Wolf RK. Intraoperative epicardial electrophysiologic mapping and isolation of autonomic ganglionic plexi. *Ann Thorac Surg*. 2007;83:538-41.
- Pappone C, Augello G, Santinelli V. Atrial fibrillation ablation. *Ital Heart J*. 2005; 6:190-9.
- Fuster V, Rydén LE, Cannom DS, Crijns HJ, Curtis AB, Ellenbogen KA, et al. ACC/AHA/ESC 2006 guidelines for the management of patients with atrial fibrillation: a report of the American College of Cardiology/American Heart Association Task Force on practice guidelines and the European Society of Cardiology Committee for Practice Guidelines (Writing Committee to Revise the 2001 guidelines for the management of patients with atrial fibrillation) developed in collaboration with the European Heart Rhythm Association and the Heart Rhythm Society. *Europace*. 2006;8:651-745.
- Yuda S, Nakatani S, Isobe F, Kosakai Y, Miyatake K. Comparative efficacy of the maze procedure for restoration of atrial contraction in patients with and without giant left atrium associated with mitral valve disease. *J Am Coll Cardiol*. 1998; 31:1097-102.
- Cox JL. Surgical treatment of atrial fibrillation: a review. *Europace*. 2004; 5(suppl):S20-9.
- Stulak JM, Sundt TM 3rd, Dearani JA, Daly RC, Orsulak TA, Schaff HV. Ten-year experience with the Cox-maze procedure for atrial fibrillation: how do we define success? *Ann Thorac Surg*. 2007;83:1319-24.
- Khargi K, Keyhan-Falsafi A, Hutten BA, Ramanna H, Lemke B, Deneke T. Surgical treatment of atrial fibrillation: a systematic review. *Eur J Cardiothorac Surg*. 2005;27:258-65.
- Saltman AE, Rosenthal LS, Francalancia NA, Lahey SJ. A completely endoscopic approach to microwave ablation for atrial fibrillation. *Heart Surg Forum*. 2003;6: E38-41.
- McClelland JH, Duke D, Reddy R. Preliminary results of a limited thoracotomy: new approach to treat atrial fibrillation. *J Cardiovasc Electrophysiol*. 2007;5:1-7.
- Sagbas E, Akpınar B, Sanisoglu I, Caynak B, Tamtekin B, Oral K, et al. Video-assisted bilateral epicardial pulmonary vein isolation for the treatment of lone atrial fibrillation. *Ann Thorac Surg*. 2007;83:1724-30.
- Haïssaguerre M, Jais P, Shah DC, Takahashi A, Hocini M, Quiniou G, et al. Spontaneous initiation of atrial fibrillation by ectopic beats originating in the pulmonary veins. *N Engl J Med*. 1998;339:659-66.
- Todd DM, Skanes AC, Guiraudon G, Guiraudon C, Krahn AD, Yee R, et al. Role of the posterior left atrium and pulmonary veins in human lone atrial fibrillation: electrophysiological and pathological data from patients undergoing atrial fibrillation surgery. *Circulation*. 2003;108:3108-14.
- Cheema A, Dong J, Dalal D, Marine JE, Henrikson CA, Spragg D, et al. Incidence and time course of early recovery of pulmonary vein conduction after catheter ablation of atrial fibrillation. *J Cardiovasc Electrophysiol*. 2007;18:387-91.
- Yamaji K, Fujimoto S, Yutani C, Hashimoto T, Nakamura S. Is the site of thrombus formation in the left atrial appendage associated with the risk of cerebral embolism? *Cardiology*. 2002;97:104-10.
- Odell JA, Blackshear JL, Davies E, Byrne WJ, Kollmorgen CF, Edwards WD, et al. Thoracoscopic obliteration of the left atrial appendage: potential for stroke reduction? *Ann Thorac Surg*. 1996;61:565-9.
- Damiano R, Voeller R. Surgical and minimally invasive ablation for atrial fibrillation. *Curr Treat Options Cardiovasc Med*. 2006;8:371-6.
- O'Neill MD, Jais P, Hocini M, Sacher F, Klein GJ, Clémenty J, et al. Catheter ablation for atrial fibrillation. *Circulation*. 2007;116:1515-23.
- Kiser AC, Wimmer-Greinecker G, Chitwood WR. Totally extracardiac maze procedure performed on the beating heart. *Ann Thorac Surg*. 2007;84:1783-5.
- Callahan TD, Natale A. Catheter ablation of atrial fibrillation. *Med Clin North Am*. 2008;92:179-201.
- Daoud EG. Percutaneous catheter ablation of atrial fibrillation. *Exp Rev Cardiovasc Ther*. 2007;5:693-705.



**Video-assisted minimally invasive surgery for lone atrial fibrillation: A clinical report of 81 cases**

Yong-qiang Cui, Yan Li, Feng Gao, Chun-lei Xu, Jie Han, Wen Zeng, Ya-ping Zeng,  
Emin Gurbanov and Xu Meng

*J Thorac Cardiovasc Surg* 2010;139:326-332

DOI: 10.1016/j.jtcvs.2009.04.029

**Continuing Medical Education Activities**

Subscribers to the Journal can earn continuing medical education credits via the Web at  
[http://cme.ctsnetjournals.org/cgi/hierarchy/ctsnetcme\\_node;JTCS](http://cme.ctsnetjournals.org/cgi/hierarchy/ctsnetcme_node;JTCS)

**Subscription Information**

This article cites 24 articles, 12 of which you can access for free at:  
<http://jtcs.ctsnetjournals.org/cgi/content/full/139/2/326#BIBL>

**Citations**

This article has been cited by 1 HighWire-hosted articles:  
<http://jtcs.ctsnetjournals.org/cgi/content/full/139/2/326#otherarticles>

**Subspecialty Collections**

This article, along with others on similar topics, appears in the following collection(s):

**Electrophysiology - arrhythmias**

[http://jtcs.ctsnetjournals.org/cgi/collection/electrophysiology\\_arrhythmias](http://jtcs.ctsnetjournals.org/cgi/collection/electrophysiology_arrhythmias) **Minimally  
invasive surgery**

[http://jtcs.ctsnetjournals.org/cgi/collection/minimally\\_invasive\\_surgery](http://jtcs.ctsnetjournals.org/cgi/collection/minimally_invasive_surgery)

**Permissions and Licensing**

General information about reproducing this article in parts (figures, tables) or in its entirety  
can be found online at:

[http://www.elsevier.com/wps/find/supportfaq.cws\\_home/permissionusematerial](http://www.elsevier.com/wps/find/supportfaq.cws_home/permissionusematerial).

An on-line permission request form, which should be fulfilled within 10 working days of  
receipt, is available at:

[http://www.elsevier.com/wps/find/obtainpermissionform.cws\\_home/obtainpermissionform](http://www.elsevier.com/wps/find/obtainpermissionform.cws_home/obtainpermissionform)